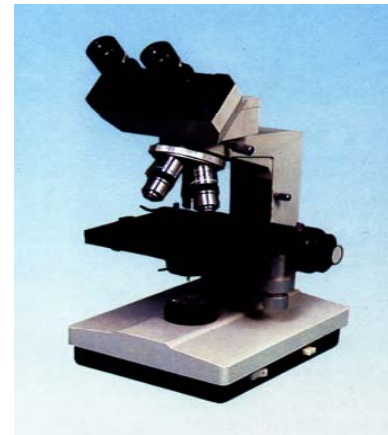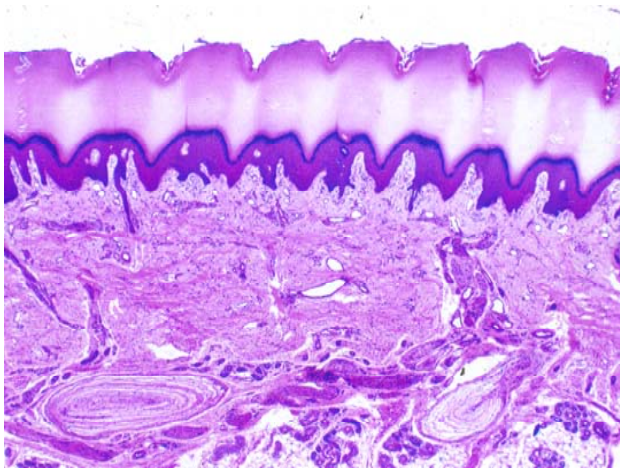



# Experimental Courseware of Histology and Embryology



**Chapter 1 Introduction and Cell**

**Chapter 2 Epithelial tissue**

**Chapter 3 Connective Tissue**

**Chapter 4 Blood**

**Chapter 5 Cartilage and Bone**

**Chapter 6 Muscle Tissue**

**Chapter 7 Nerve Tissue**

**Chapter 8 Circulatory System**

**Chapter 9 Immune System**

**[Chapter 10 Skin](#)**

**Chapter 11 Digestive Tract**

**Chapter 12 Digestive Gland**

**Chapter 13 Respiratory System**

**Chapter 14 Urinary System**

**Chapter 15 Endocrine System**

**Chapter 16 Sense Organ**

**Chapter 17 Male Reproduction**

**Chapter 18 Female Reproduction**

**Chapter 19 Embryology 1**

**Chapter 20 Embryology 2**

# CHAPTER 10 The skin and Its Appendages

I Questions

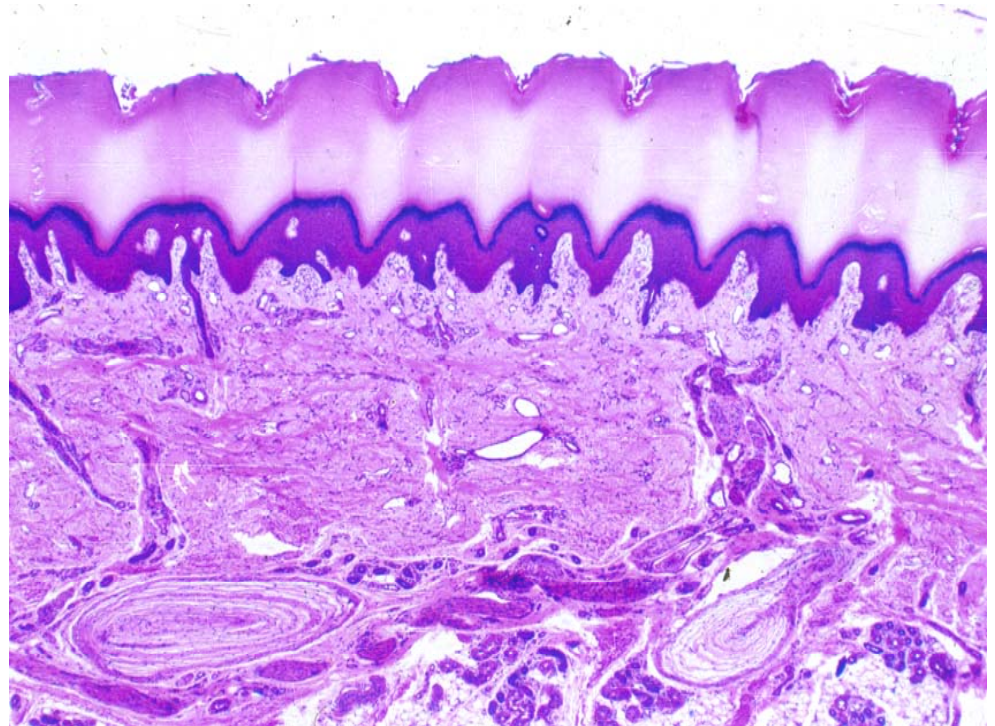
II [Slides](#)

III Sections

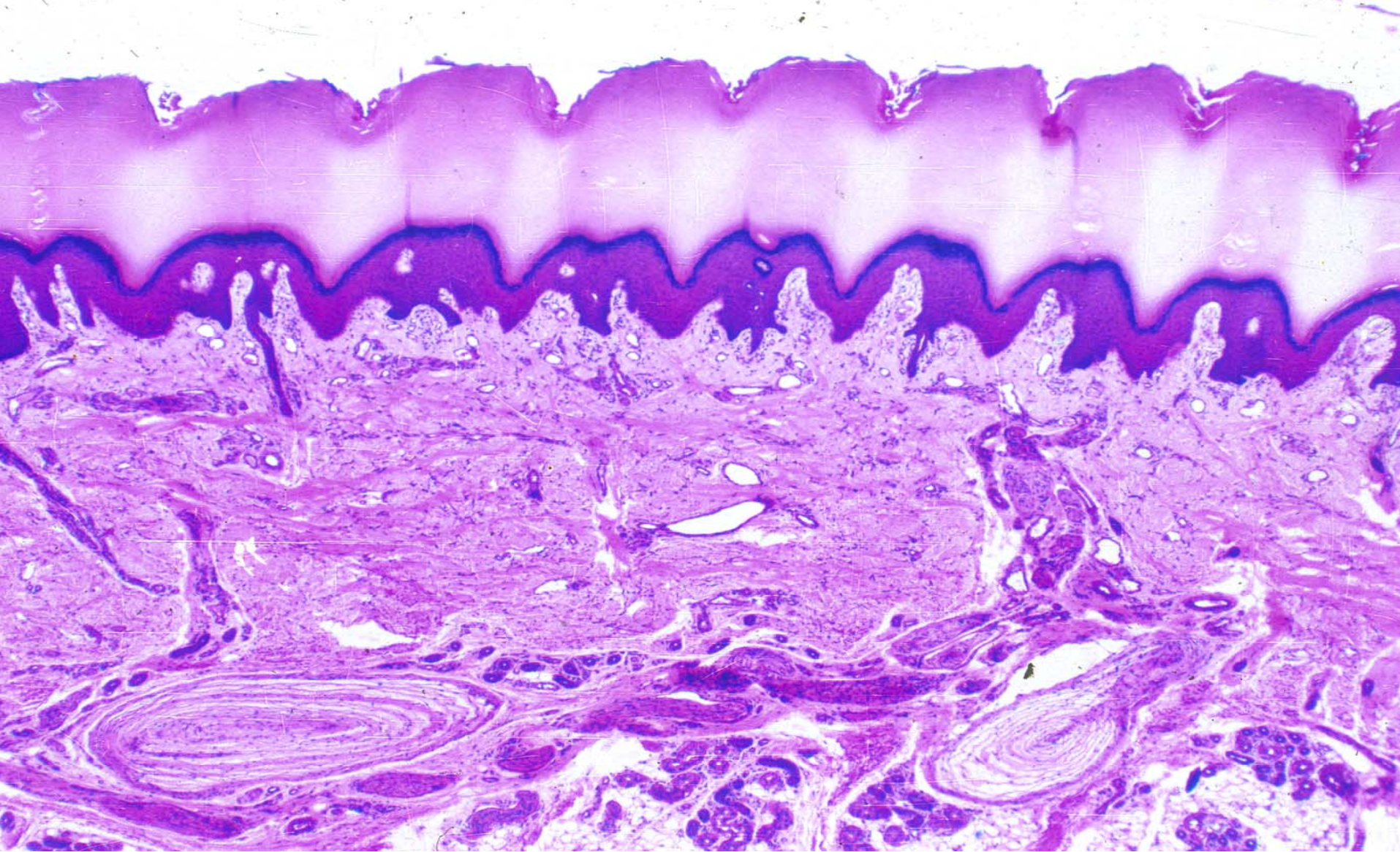
[NO.45 skin of the sole](#)

[NO.46 skin of the hair](#)

[NO.47 skin of the body](#)

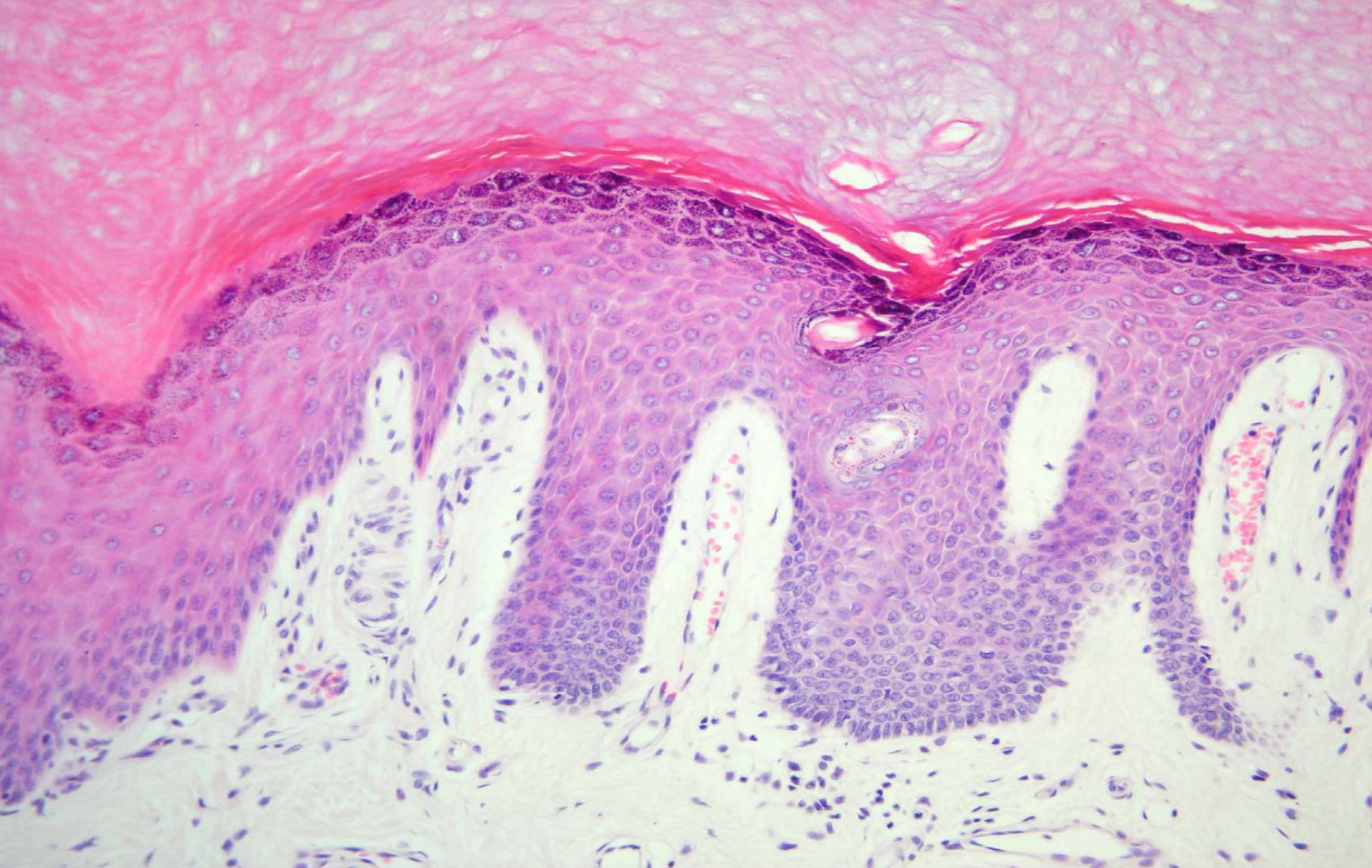






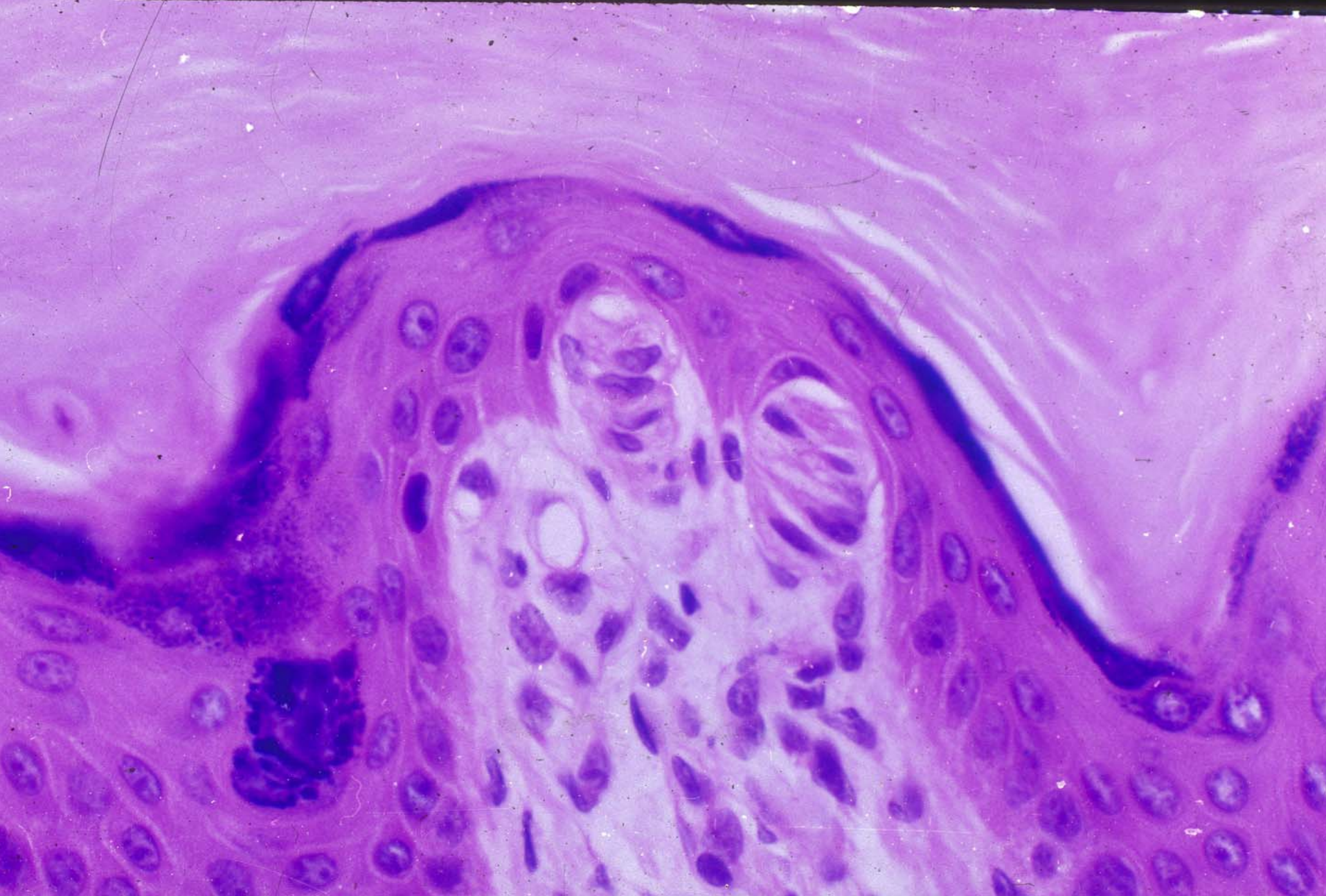
skin of human sole





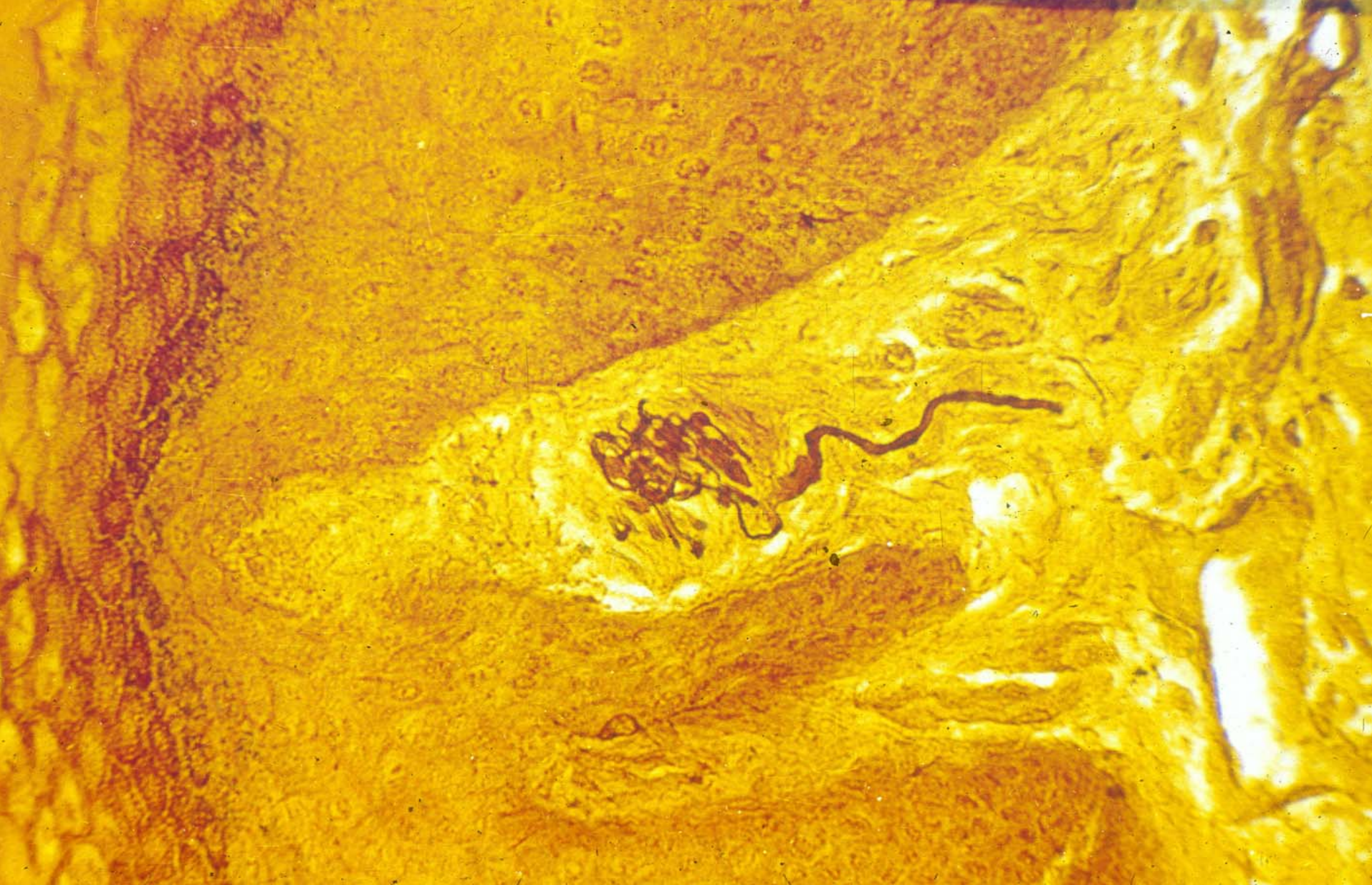
epidermis





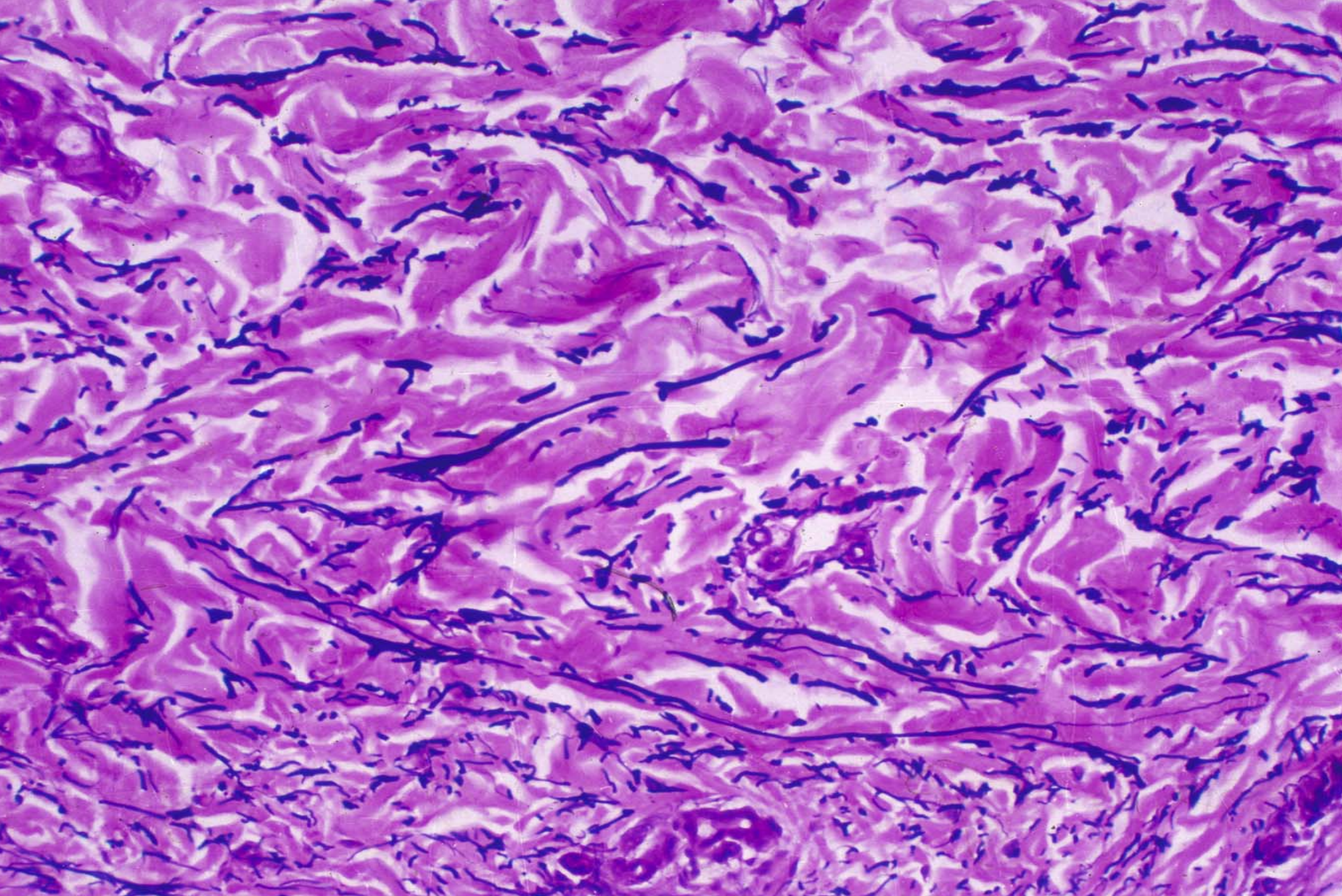
Epidermis, papillary layer and tactile corpuscle





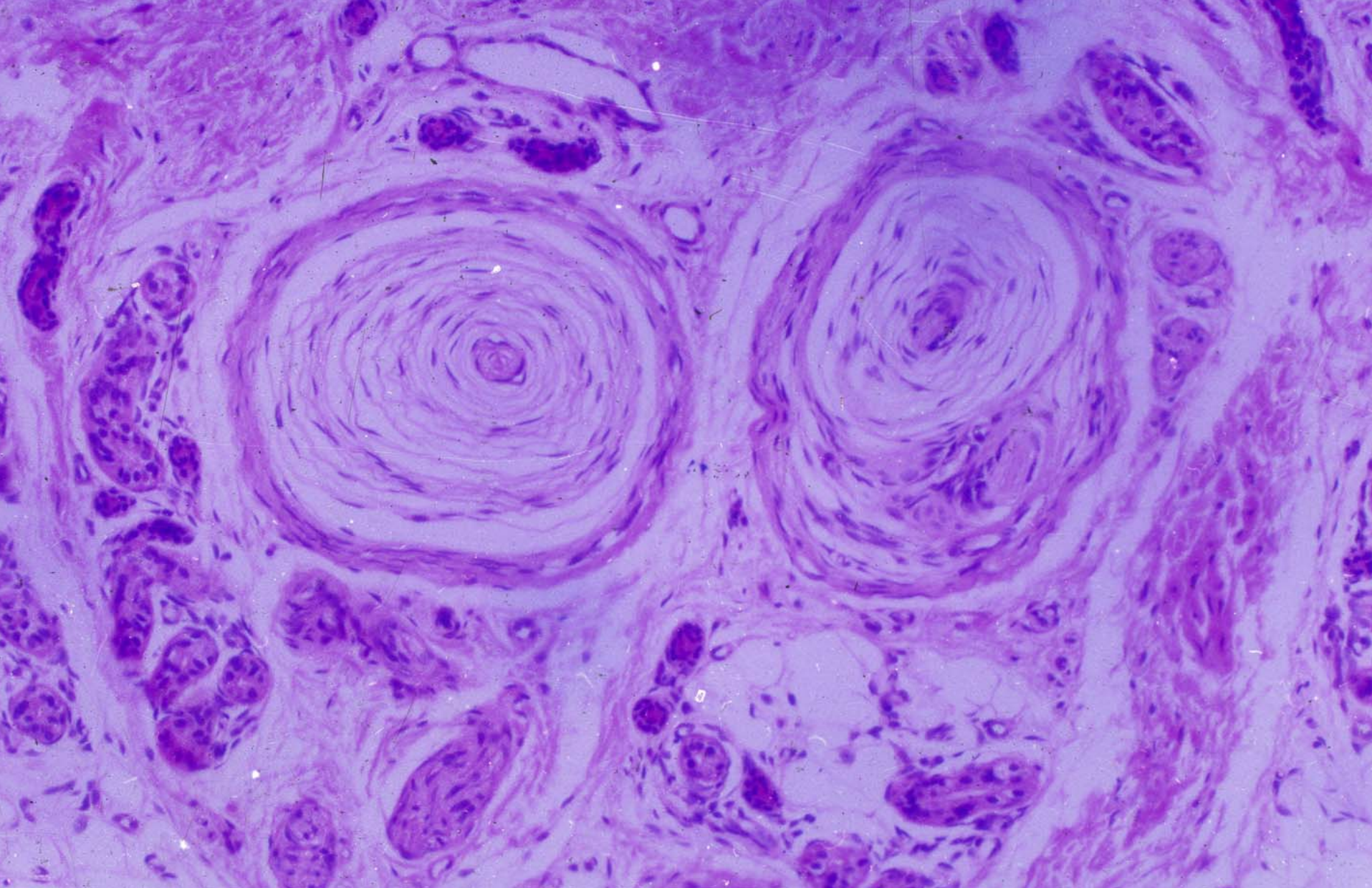
papillary layer and tactile corpuscle





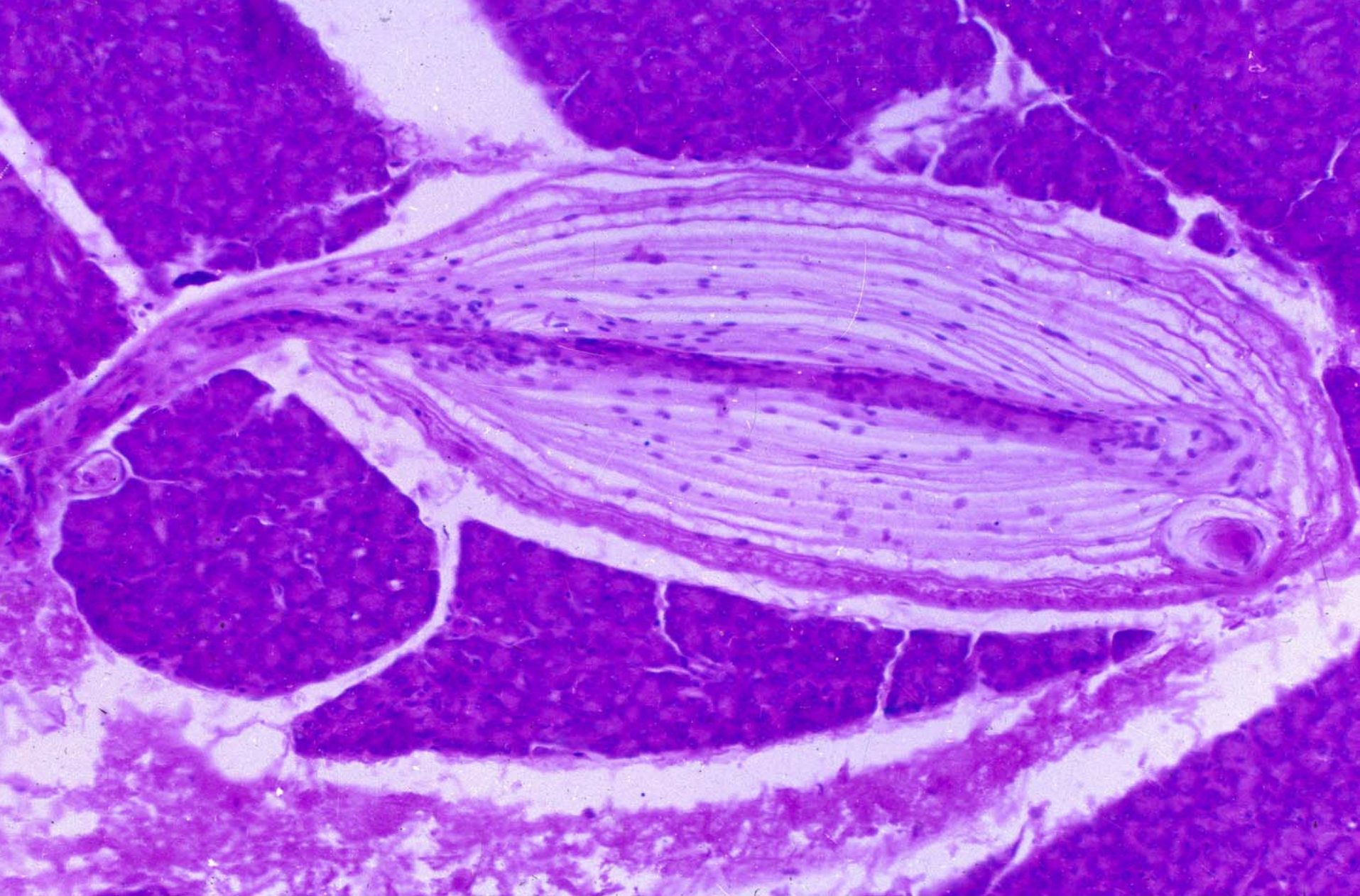
Reticular layer





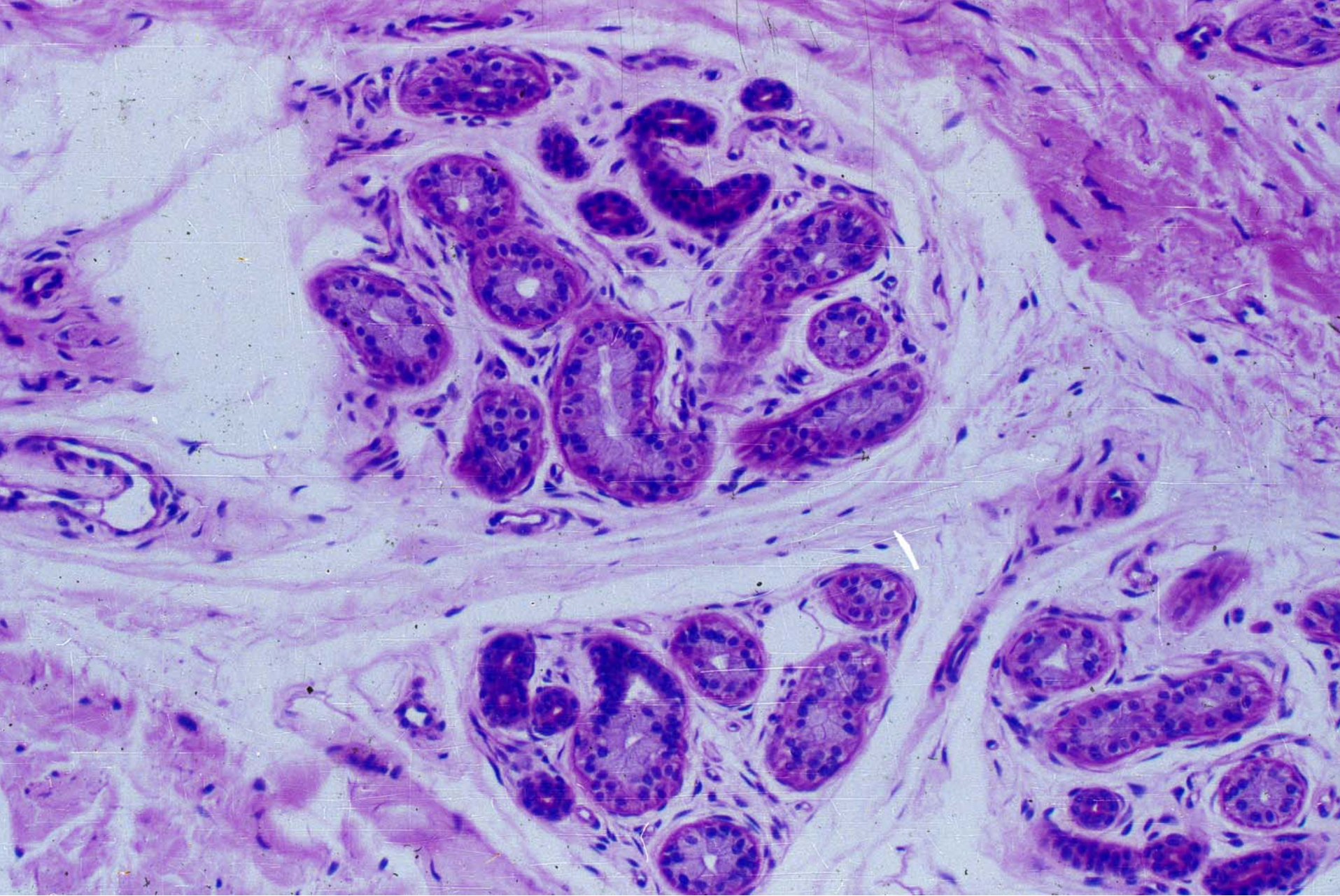
Lamellar corpuscle





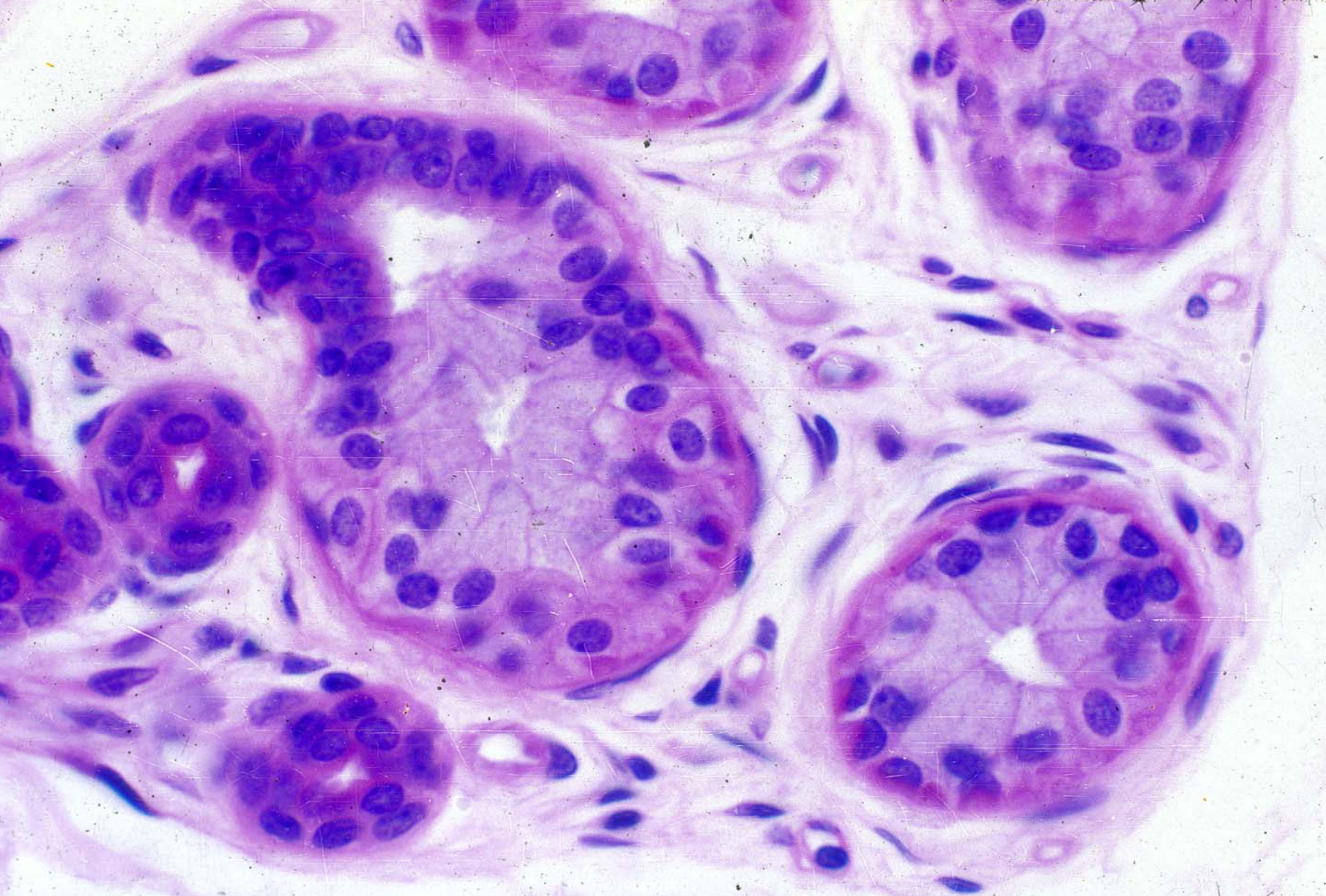
Lamellar corpuscle





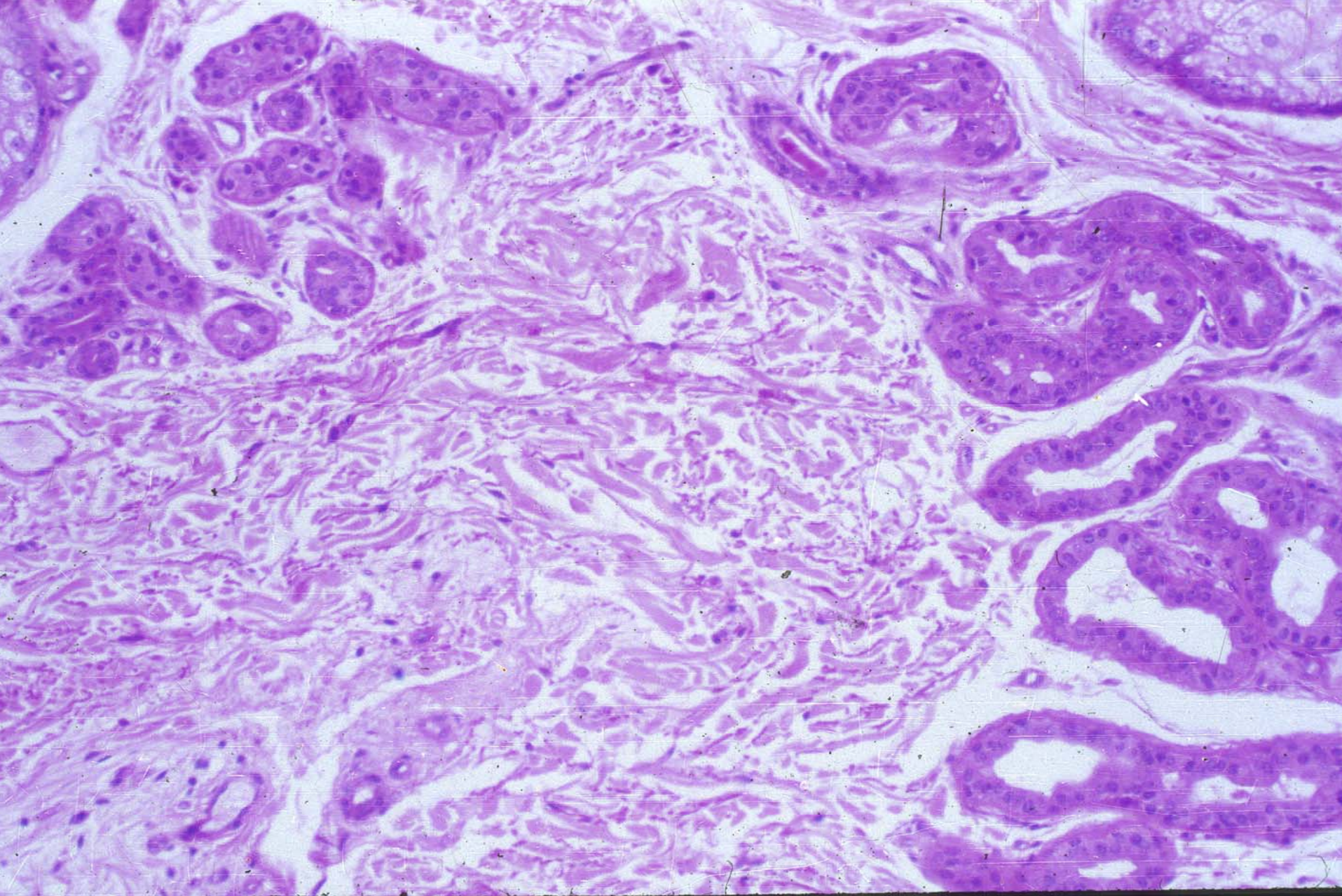
Eccrine sweat gland





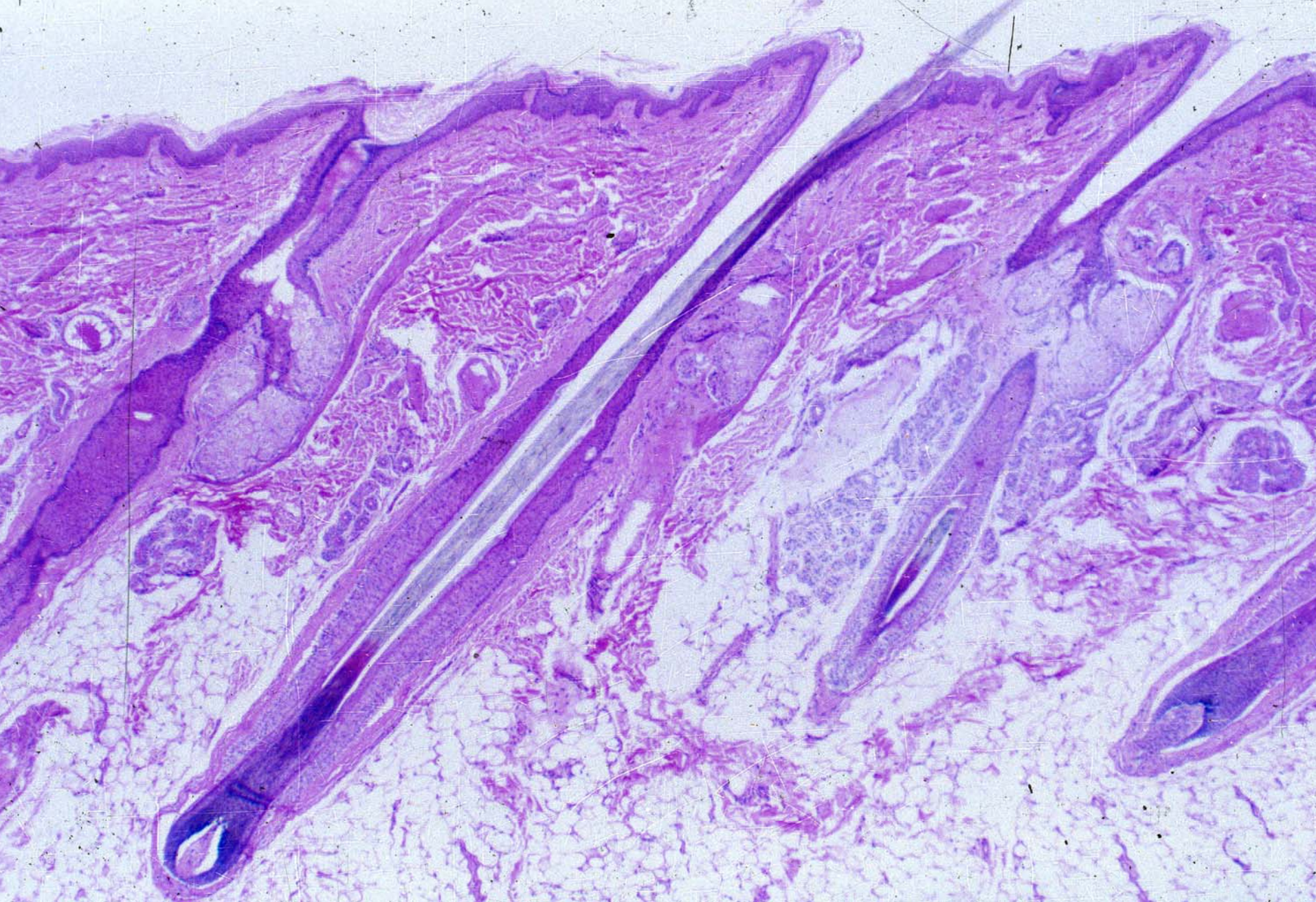
Eccrine sweat gland





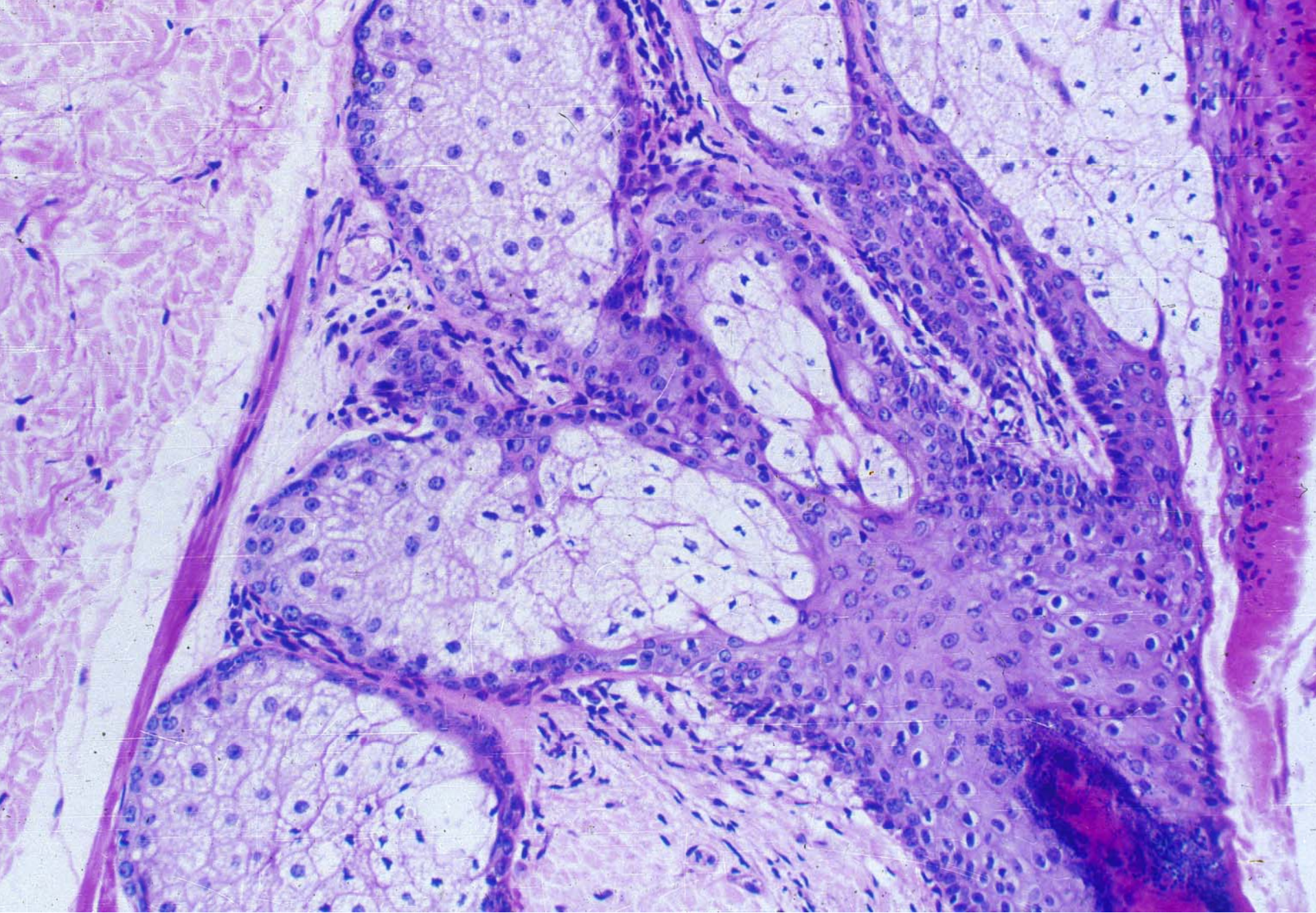
Apocrine sweat gland





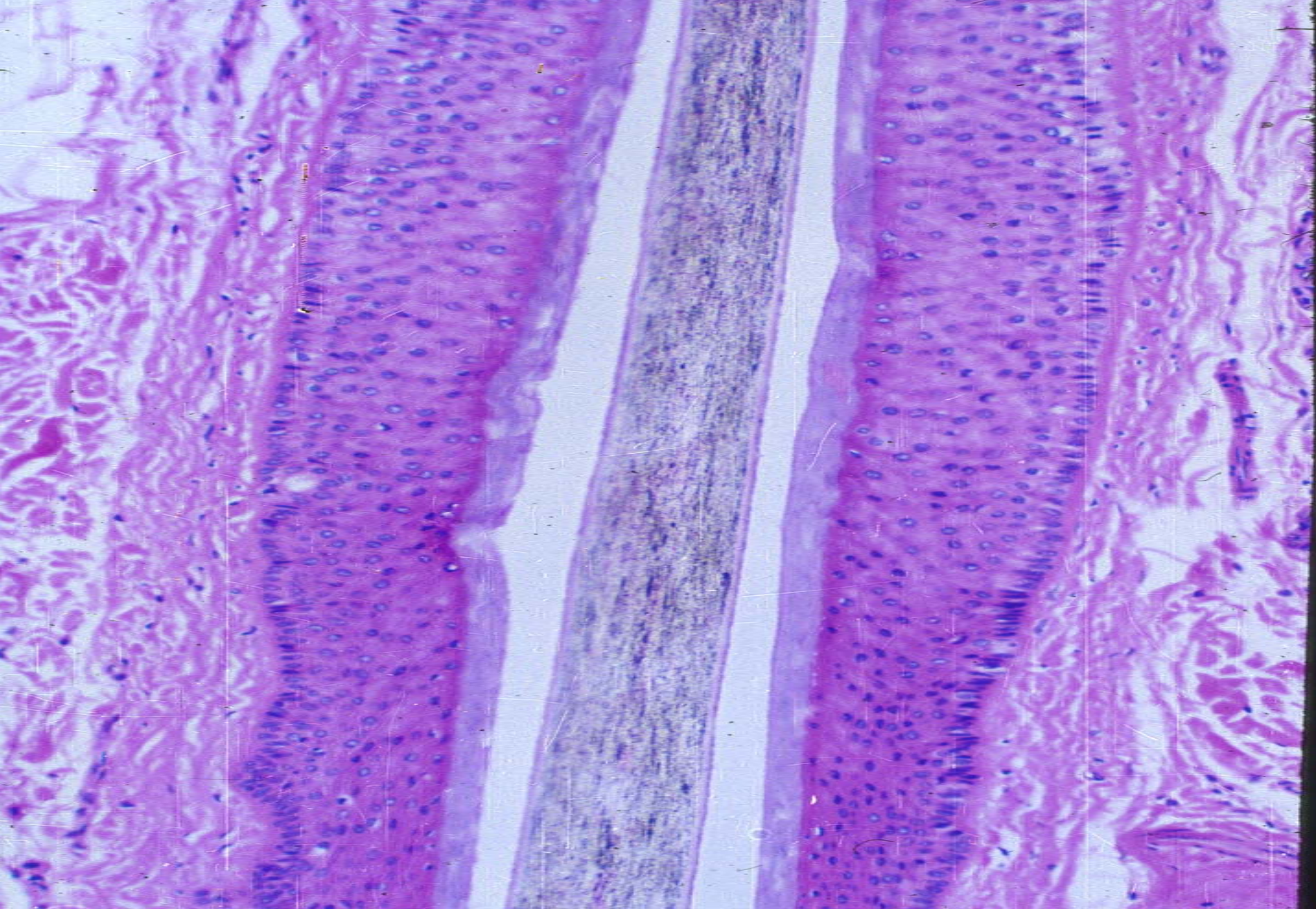
Skin of the hair and appendages





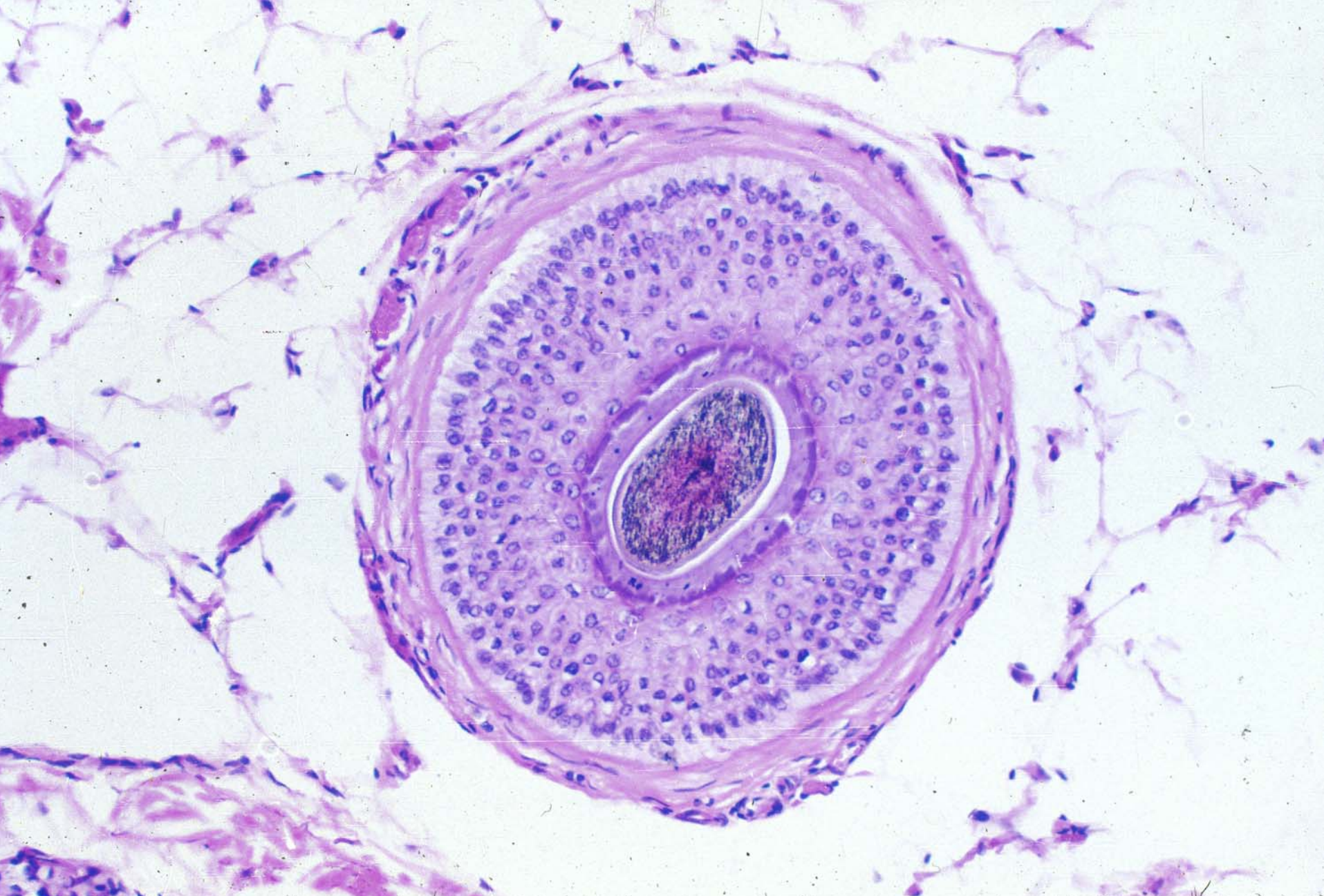
Sebaceous gland and arrector pili muscle





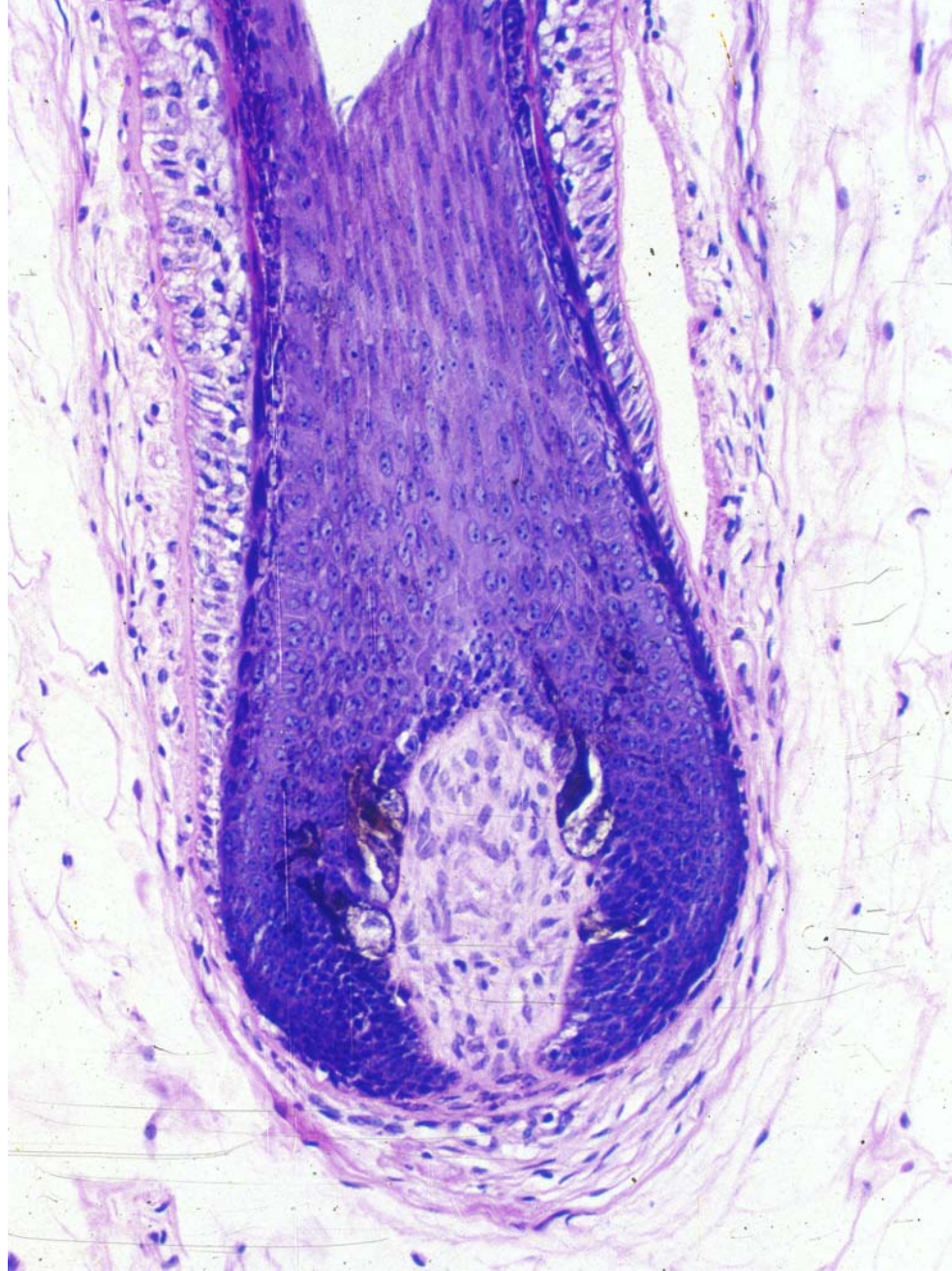Hair root and hair follicle





Hair root and hair follicle





Hair bulb and hair papilla



## Questions:

1. The layers and functions of skin.

2. The structure of epidermis

(1) Kinds of keratinocyte and formation of stratum corneum.

(2) Kinds and functions of nonkeratinocyte.

3. The structure and functions of hypodermis.

4. Appendages of skin.



